

How to read an electrocardiogram (ECG). Part One: Basic principles of the ECG. The normal ECG

Dallas Price, Consultant Cardiologist, St Mary's Hospital, Isle of Wight, UK

Introduction

The electrocardiogram (ECG) is one of the simplest and oldest cardiac investigations available, yet it can provide a wealth of useful information and remains an essential part of the assessment of cardiac patients. With modern machines, surface ECGs are quick and easy to obtain at the bedside and are based on relatively simple electrophysiological concepts. However junior doctors often find them difficult to interpret. This is the first in a short series of articles that aim to:

- Help readers understand and interpret ECG recordings.
- Reduce some of the anxiety juniors often experience when faced with an ECG.

Basic principles

What is an ECG?

An ECG is simply a representation of the electrical activity of the heart muscle as it changes with time, usually printed on paper for easier analysis. Like other muscles, cardiac muscle contracts in response to electrical *depolarisation* of the muscle cells. It is the sum of this electrical activity, when amplified and recorded for just a few seconds that we know as an ECG.

Basic electrophysiology of the heart (see Figure 1)

The normal cardiac cycle begins with spontaneous depolarisation of the sinus node, an area of specialised tissue situated in the high right atrium (RA). A wave of electrical depolarisation then spreads through the RA and across the inter-atrial septum into the left atrium (LA).

The atria are separated from the ventricles by an electrically inert fibrous ring, so that in the normal heart the only route of transmission of electrical depolarisation from atria to ventricles is through the atrioventricular (AV) node. The AV node delays the electrical signal for a short time, and then the wave of depolarisation spreads down the interventricular septum (IVS), via the bundle of His and the right and left bundle branches, into the right (RV) and left (LV) ventricles. Hence with normal conduction the two ventricles contract simultaneously, which is important in maximising cardiac efficiency.

After complete depolarisation of the heart, the myocardium must then *repolarise*, before it can be ready to depolarise again for the next cardiac cycle.

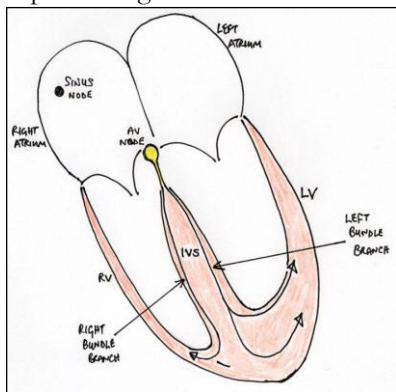


Figure 1. Basic electrophysiology of the heart

Electrical axis and recording lead vectors (see Figures 2 and 3)

The ECG is measured by placing a series of electrodes on the patient's skin – so it is known as the 'surface' ECG.

The wave of electrical depolarisation spreads from the atria down through the IVS to the ventricles. So the direction of this depolarisation is usually from the superior to the inferior aspect of the heart. The direction of the wave of depolarisation is normally towards the left due to the leftward orientation of the heart in the chest and the greater muscle mass of the left ventricle than the right. This overall direction of travel of the electrical depolarisation through the heart is known as the *electrical axis*.

A fundamental principle of ECG recording is that when the wave of depolarisation travels toward a recording lead this results in a positive or upward deflection. When it travels away from a recording lead this results in a negative or downward deflection.

The electrical axis is normally downward and to the left but we can estimate it more accurately in individual patients if we understand from which 'direction' each recording lead measures the ECG.

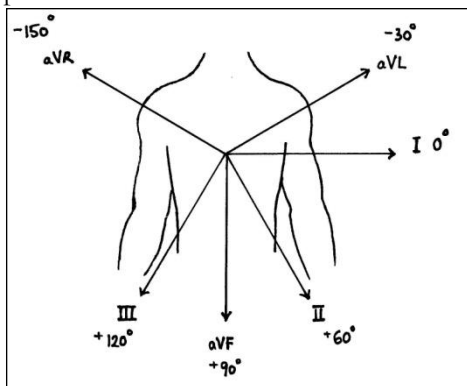


Figure 2. Orientation of the limb leads showing the direction from which each lead 'looks' at the heart

By convention, we record the standard surface ECG using 12 different recording lead 'directions,' though rather confusingly only 10 recording electrodes on the skin are required to achieve this. Six of these are recorded from the chest overlying the heart – *the chest or precordial leads*. Four are recorded from the limbs – *the limb leads*. It is essential that each of the 10 recording electrodes is placed in its correct position, otherwise the appearance of the ECG will be changed significantly, preventing correct interpretation.

The limb leads record the ECG in the coronal plane, and so can be used to determine the electrical axis (which is usually measured only in the coronal plane). The limb leads are called leads I, II, III, AVR, AVL and AVF. Figure 2 shows the relative directions from which they 'look' at the heart. A horizontal line through the heart and directed to the left (exactly in the direction of lead I) is conventionally labelled as the reference point of 0 degrees (0°). The directions from which other leads 'look' at the heart are described in terms of the angle in degrees from this baseline.

The electrical axis of depolarisation is also expressed in degrees and is normally in the range from -30° to $+90^\circ$. A detailed explanation of how to determine the axis is beyond the scope of this article but the principles mentioned here should help readers to understand the concepts involved.

The chest leads record the ECG in the transverse or horizontal plane, and are called V1, V2, V3, V4, V5 and V6 (see Figure 3).

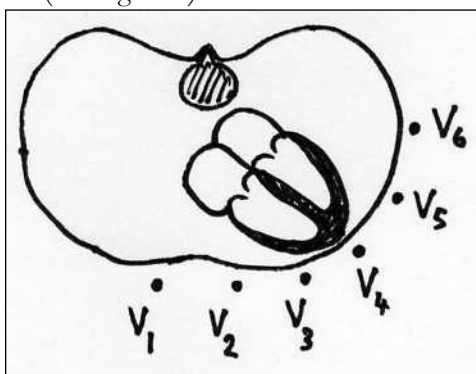


Figure 3. Transverse section of the chest showing the orientation of the six chest leads in relation to the heart

Voltage and timing intervals

It is conventional to record the ECG using standard measures for amplitude of the electrical signal and for the speed at which the paper moves during the recording. This allows:

- Easy appreciation of heart rates and cardiac intervals and
- Meaningful comparison to be made between ECGs recorded on different occasions or by different ECG machines.

The amplitude, or voltage, of the recorded electrical signal is expressed on an ECG in the vertical dimension and is measured in millivolts (mV). On standard ECG paper 1mV is represented by a deflection of 10 mm. An

increase in the amount of muscle mass, such as with left ventricular hypertrophy (LVH), usually results in a larger electrical depolarisation signal, and so a larger amplitude of vertical deflection on the ECG.

An essential feature of the ECG is that the electrical activity of the heart is shown as it varies with time. In other words we can think of the ECG as a graph, plotting electrical activity on the vertical axis against time on the horizontal axis. Standard ECG paper moves at 25 mm per second during real-time recording. This means that when looking at the printed ECG a distance of 25 mm along the horizontal axis represents 1 second in time.

ECG paper is marked with a grid of small and large squares. Each small square represents 40 milliseconds (ms) in time along the horizontal axis and each larger square contains 5 small squares, thus representing 200 ms. Standard paper speeds and square markings allow easy measurement of cardiac timing intervals. This enables calculation of heart rates and identification of abnormal electrical conduction within the heart (see Figure 4).

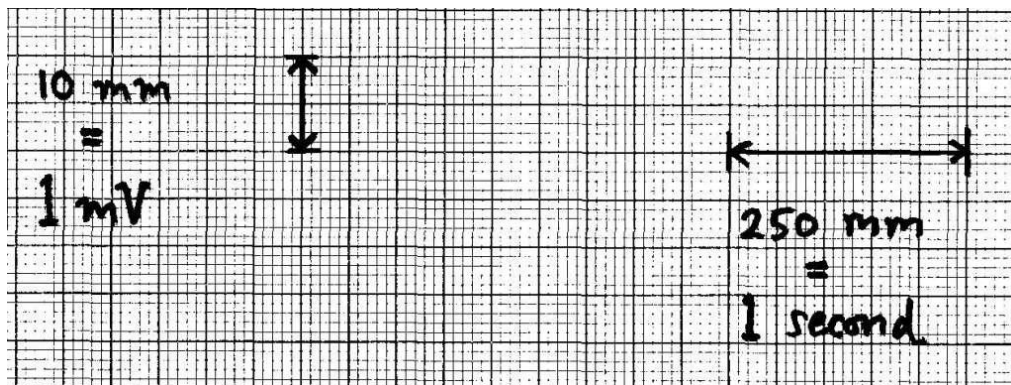


Figure 4. Sample of standard ECG paper showing the scale of voltage, measured on the vertical axis, against time on the horizontal axis

The normal ECG

It will be clear from above that the first structure to be depolarised during normal sinus rhythm is the right atrium, closely followed by the left atrium. So the first electrical signal on a normal ECG originates from the atria and is known as the **P wave**. Although there is usually only one P wave in most leads of an ECG, the P wave is in fact the sum of the electrical signals from the two atria, which are usually superimposed.

There is then a short, physiological delay as the atrioventricular (AV) node slows the electrical depolarisation before it proceeds to the ventricles. This delay is responsible for the PR interval, a short period where no electrical activity is seen on the ECG, represented by a straight horizontal or 'isoelectric' line.

Depolarisation of the ventricles results in usually the largest part of the ECG signal (because of the greater muscle mass in the ventricles) and this is known as the **QRS complex**.

- The Q wave is the first initial downward or 'negative' deflection
- The R wave is then the next upward deflection (provided it crosses the isoelectric line and becomes 'positive')
- The S wave is then the next deflection downwards, provided it crosses the isoelectric line to become briefly negative before returning to the isoelectric baseline.

In the case of the ventricles, there is also an electrical signal reflecting repolarisation of the myocardium. This is shown as the **ST segment** and the **T wave**. The ST segment is normally isoelectric, and the T wave in most leads is an upright deflection of variable amplitude and duration (see Figures 5 and 6).

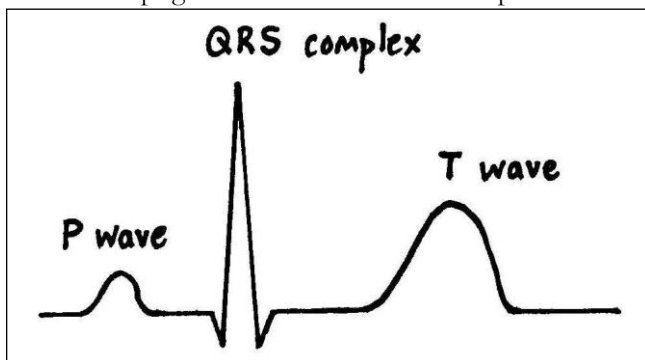


Figure 5. The major waves of a single normal ECG pattern

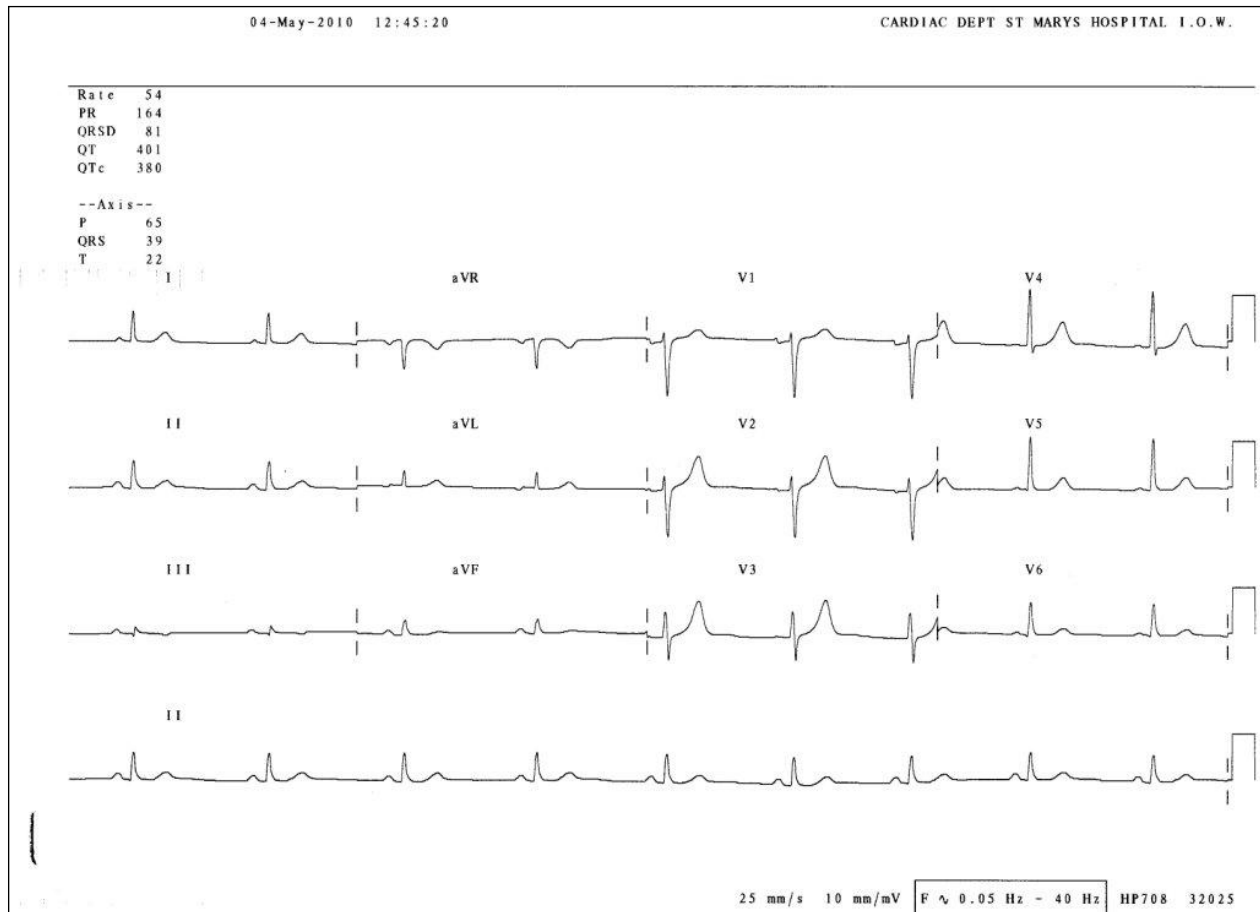


Figure 6. Example of a normal 12 lead ECG; notice the downward deflection of all signals recorded from lead aVR. This is normal, as the electrical axis is directly away from that lead

Normal intervals

The recording of an ECG on standard paper allows the time taken for the various phases of electrical depolarisation to be measured, usually in milliseconds. There is a recognised normal range for such 'intervals':

- **PR interval** (measured from the beginning of the P wave to the first deflection of the QRS complex). Normal range 120 – 200 ms (3 – 5 small squares on ECG paper).
- **QRS duration** (measured from first deflection of QRS complex to end of QRS complex at isoelectric line). Normal range up to 120 ms (3 small squares on ECG paper).
- **QT interval** (measured from first deflection of QRS complex to end of T wave at isoelectric line). Normal range up to 440 ms (though varies with heart rate and may be slightly longer in females)

Heart rate estimation from the ECG

Standard ECG paper allows an approximate estimation of the heart rate (HR) from an ECG recording. Each second of time is represented by 250 mm (5 large squares) along the horizontal axis. So if the number of large squares between each QRS complex is:

- 5 - the HR is 60 beats per minute.
- 3 - the HR is 100 per minute.
- 2 - the HR is 150 per minute.